

Evidence-Based Homoeopathy: A Case of Vernal Keratoconjunctivitis

Posted By *Sandeep Sathye* On August 18, 2017 @ 8:50 am In Clinical Cases | [No Comments](#)

Introduction:

Vernal Keratoconjunctivitis (VKC) or spring catarrh is a recurrent, seasonal, bilateral allergic inflammation of the conjunctiva common in children and young adults especially in males. It is common in tropical countries with incidence in summer season while in some patients disease tends to persist throughout the year with acute exacerbation in summer. It is caused by a delayed hypersensitive reaction to exogenous allergens such as dust, pollens, heat etc., and family history of atopy is common. The main symptoms are intense itching, redness, foreign body sensation, burning, photophobia, thick mucus discharge and sometimes ptosis of eyelids giving a sleepy look. It occurs in three varieties as bulbar, palpebral and mixed form. The Bulbar or Limbal variety is common and is associated with formation of mucoid nodules at the limbus, while in the palpebral variety on everting the upper lid there is an appearance of hypertrophied conjunctiva in the form of polygonal, flat topped papillae that causes pseudo-ptosis of the eyelid. The cornea may get involved in both varieties leading to superficial punctate keratitis, shield ulceration and pseudogerontoxon (ring opacity) that may affect the vision. Onset of VKC is usually after the age of 5 years and usually resolved around the time of puberty.

Conventional treatment is purely symptomatic and includes use of topical steroids, NSAID, mast cell stabilizer, antihistaminics etc., which give only a temporary relief. Out of these, steroids give a dramatic relief of symptoms but if used for a prolonged period can lead to blinding complications such as cataract, glaucoma, non-healing corneal ulcers, fungal infections etc. So there is great need to have a safe and effective alternative line of treatment in the management of this disease. Taking into account the chronic nature and systemic association of disease, a systemic approach of treatment with homoeopathy was considered

CASE REPORT:

History: A boy aged 12 years presented in the Out-patient Department of the institute on June 28, 2003 with the complaints of repeated redness and itching of eyes for the last 7 years. Initially complaints used to occur only in summer but for the last 2 years they were present throughout the year. There were also complaints of foreign body sensation after rubbing the eyes, whitish-yellow ropy discharge from eye and glaring of light especially in the morning after waking for the last 2 years.

It was diagnosed as a case of VKC and was given topical steroids and non-steroidal anti-inflammatory drugs by an eye specialist. The patient's past history revealed repeated upper respiratory tract infection after every 4 to 6 months for the last 3 to 4 years and repeated stomatitis after every 3 to 4 months for the last 2 years. There was a past history of eruptions

on back and abdomen in every summer for 3 years. His mother was myopic and had allergy to artificial ear rings.

Examination : Patient was of average build with a medium complexion. On eye examination, there was a partial dropping of eyelids and in right eye there was a refractive error of -0.5 diopter cylinder at 40 degrees while in left eye -1.0 diopter at 150 degree. On Slit-lamp biomicroscopy examination, conjunctiva showed limbal papillae in left eye at inferio-nasal quadrant while palpebral papillae in both eyes more in left eye (Figure 1A, 1B). Corneal examination showed ring opacity in both eyes and punctate epithelial keratitis involving upper quadrant in left eye.

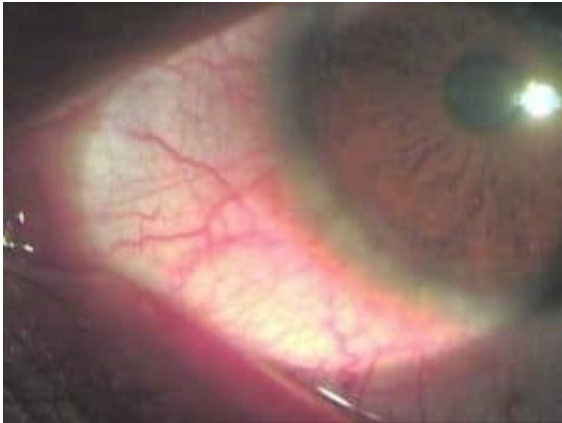

Figure 1 A : Limbal papillae in left eye before starting the treatment.

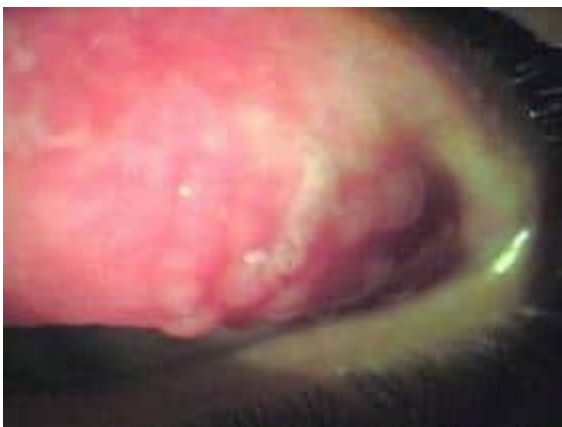

Figure 1 B : Palpebral papillae in left upper eyelid before starting the treatment.

Homoeopathic Case workup and Intervention:

General symptoms – *Physical generals* – Hot in thermal nature with desire for salt and aversion for milk. Sleeps many times on abdomen with feet uncovered.

Mental generals – Fear of darkness and weeps easily if scolded.

Miasmatic Expression – Psora and Sycosis.

Itching, redness of eyes, past & family history of skin allergy, fearful nature covers psora, while yellow discharge, granular lids covers a sycotic miasm.

Chronic totality of symptoms and rubrics for Repertorisation (figure 2) –

Mind – Fear : Dark.

Appetite – Aversion to : Milk.

Stomach – Desires: Salt things.

Sleep – Position during sleep : Lying on abdomen.

Extremities – Uncover, inclination to : Lower limbs : Feet.

Result of Repertorisation : Pulsatilla – 4 /9, Carbo veg. – 3 /7, Sulphur – 3 /6.

Medicines selected –

Constitutional medicine – Pulsatilla nigricans.

Reasons to select: hot remedy & covers psora, sycotic miasm with mental nature.

Intercurrent medicines – Medorrhinum and Sulphur

Medorrhinum – anti-sycotic, hot remedy, sleeps on abdomen with feet uncovered.

Sulphur – anti-psoric, hot remedy, aversion to milk, sleeps with feet uncovered.

Acute totality of symptoms and rubrics for Repertorisation (figure 3) –

Eye – Photophobia : morning.

Eye – Itching.

Eye –

Eye – Conjunctiva : Discharge : Creamy.

Eye : Granular : Lids.

Result of Repertorisation with gradation of symptoms : Nux-vom. 4 /10, Pulsatilla – 4 /10, Silicea – 4 /10, Nat sulph. – 5 /8.

Acute medicine selected – Natrum sulphuricum and Nux. Vomica.

Basis of prescription: photophobia in the morning and granular lids.

1st prescription – Natrum sulph. 30C, TDS for 2 weeks followed by HS, 2 weeks as sycosis was a dominating miasm in this case.

| Remedy Name | Puls | Carbo-v | Sulph | Hels | Argem | Lac-c | Asst | By |
|--|------|---------|-------|------|-------|-------|------|----|
| Totality | 0 | 7 | 6 | 4 | 3 | 3 | 3 | 2 |
| Symptom Covered | 4 | 3 | 3 | 2 | 1 | 1 | 1 | 1 |
| [KT] [Mind]Fear (see anxiety): Dark: | 2 | 2 | | | | | | |
| [BN] [Appetite]Aversion to:Milk: | 2 | 2 | 2 | 1 | | | 2 | 2 |
| [KT] [Stomach]Desires:Salt things: | | 3 | 1 | 3 | 3 | 3 | | |
| [BN] [Sleep]Positions during sleep:Lying on abdomen: | 1 | | | | | | | |
| [KT] [Extremities]Uncover,inclination to:Lower limbs:Feet: | 2 | | 2 | | | | | |

Figure 2 : Repertorisation Chart for Constitutional treatment.

| Remedy Name | Hell-v | Puls | Sil | Hels | Argem | Sulph | Asst | Calc | Hell-v |
|---|--------|------|-----|------|-------|-------|------|------|--------|
| Totality | 10 | 10 | 10 | 8 | 8 | 8 | 7 | 7 | 7 |
| Symptom Covered | 4 | 4 | 4 | 3 | 3 | 3 | 3 | 3 | 3 |
| [KT] [Eye]Photophobia:Morning: | 3 | | 1 | 2 | | | | 2 | |
| [BN] [Eyes]Itching: | 2 | 3 | 4 | 1 | | 4 | 1 | 4 | 2 |
| [BN] [Eyes]Red: | 3 | 2 | 3 | 1 | 3 | 2 | 3 | 1 | 3 |
| [BR] [Eyes]Conjunctiva:Discharge: Creamy: | | 3 | | 2 | 3 | | | | |
| [KT] [Eye]Granular:Lids: | 2 | 2 | 2 | 2 | 2 | 2 | 3 | | 2 |

Figure 3 : Repertorisation Chart for Acute treatment

Follow-up and Outcomes

August 16, 2003: there was reduction of itching, redness of eyes, photophobia as well as discharge. So *Natrum sulphuricum* 30C was continued in BD dose for 4 weeks.

November 22, 2003: patient reported after almost 3 months with further reduction of itching and redness but photophobia and discharge were same. On eye examination there was a reduction of conjunctival congestion and limbal papillae but palpebral papillae has not reduced. Vision examination, there was a reduction of myopic astigmatism up to -0.25 diopters in both eyes.

Patient was prescribed *Medorrhinum* 1M, single HS dose followed by placebo for 4 weeks.

February 2, 2004: There was a further in intensity of redness, itching, discharge and photophobia. On eye examination, there was a further reduction of limbal papillae but no much reduction of palpebral papillae. Patient had history of diarrhea 2 weeks back and took medication from family doctor. So *Nux. vomica* 30C, BD dose was given for 2 weeks to antidote the effects of conventional medicines as well as to reduce granular lids.

February 14, 2004: All eye complaints and papillae reduced but not subsided completely, so a constitutional medicine *Pulsatilla* 1M, single HS dose was given followed by a placebo for 4 weeks.

April 24, 2004: Eye complaints subsided except occasional itching of eyes that used to occur if he does excess reading. On eye examination palpebral papillae in right eye has subsided but not in left eye. So *Pulsatilla* 10M, single dose at night followed by a placebo in HS dose for 4 weeks was prescribed.

August 28, 2004: There were no eye complaints for last 3 months as well as no incidence of URTI for last 8 month. Similarly episode of repeated stomatitis has subsided but patient complained of itching of skin on abdomen in hypogastric region for last 1 month.

Sulphur 30C, one dose daily for a week was given in order to cover psoric symptom and was followed by placebo for 2 weeks.

December 8, 2004 : patient reported after almost 3 months with no skin complaints, similarly he had not noticed any ocular complaints. Eye examination also showed complete absence of bulbar and palpebral papillae. (figure 4A, 4B- below)

May 21, 2005 : patient had no ocular or general complaints in summer season. On eye examination there was a complete reduction of astigmatism in right eye.

December 31, 2005 : no ocular signs and symptoms on eye examination.

May 13, 2006 : came for routine eye checkup with no recurrence of ocular or general complaints and eye had a normal appearance.

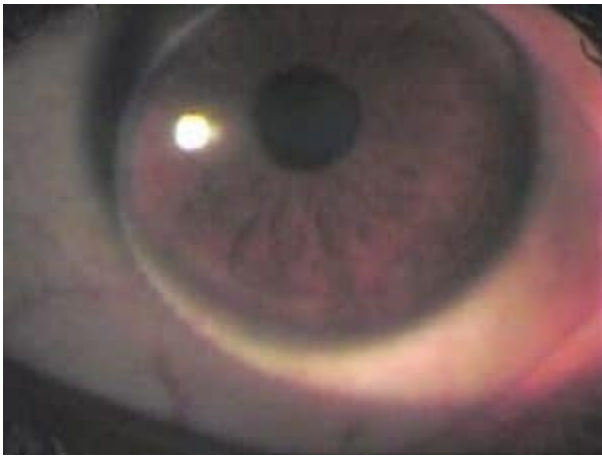


Figure 4 A : Reduction of limbal papillae after treatment.

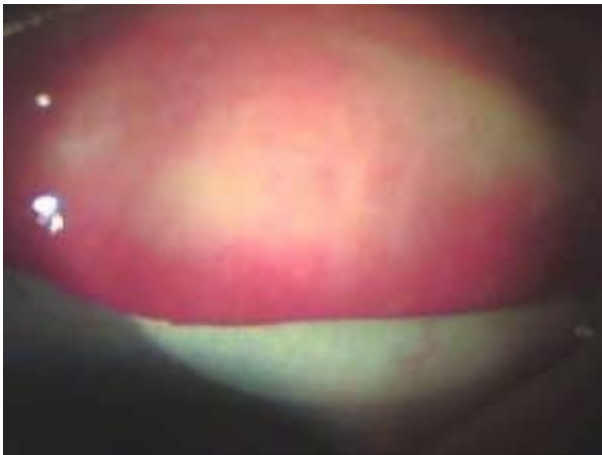

Figure 4 B : Reduction of palpebral papillae after treatment.

CONCLUSIONS:

Photographic documentary evidence in this case shows that use of systemic homoeopathic medicines not only give symptomatic relief in the acute phase of disease but also help to prevent its recurrence along with an improvement in the general health of the patient. Homoeopathic medicines being sweet and easy to administer, result in the patient taking it regularly and showing better compliance. Homoeopathy is a better alternative in the treatment of VKC.

Article printed from Homeopathy: <https://hpathy.com>

URL to article: <https://hpathy.com/clinical-cases/evidence-based-homoeopathy-case-vernal-keratoconjunctivitis/>

Copyright © 2016 Hpathy.com. All rights reserved.